

Protozoa: Exercise 12

35. Describe trophozoite and cyst stages

What stage of a protozoa's life is it metabolically active, feeding, capable of motion and found in fresh, warm stool samples?

Trophozoites stage

- This stage causes patients to have symptoms.
- Best view while stool still warm

What stage of a protozoa's life is it inactive (dormant)?

Cyst stage

- Will have a regular shape (oval or circle) than in the troph stage

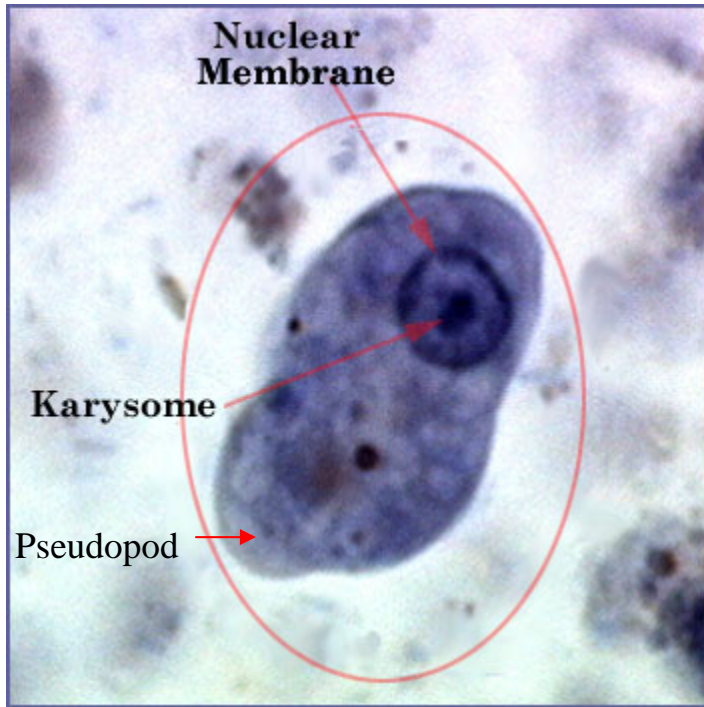
36. With the aid of your drawings on p.12-17 and 12-18, identify:

Entamoeba histolytica trophozoites and cyst

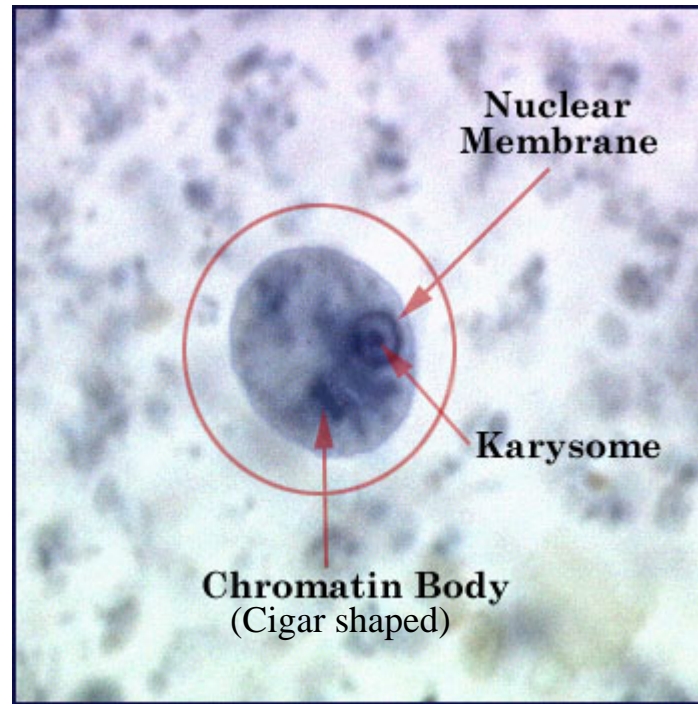
Class *Sarcodina*

Mode of Locomotion: Pseudopods (False feet)

Scientific Name/ Common Name	Disease	Size/Shape	Laboratory Diagnostic	Source of Infection/ Intermediate Host/Vector	Sign/Symptoms	Treatments	Stats
<i>Entamoeba histolytica</i>	Amoebic dysentery (infection of intestines)		Cysts or trophs in stool	Cysts in food & water or feces	Bloody diarrhea, dehydration	Metronidazole (Flagyl)	<ul style="list-style-type: none"> • 10% world affected • 50% population in some countries



Troph



Cysts

Look for:

Nucleus will contain a dark stained dot called a Karysome.

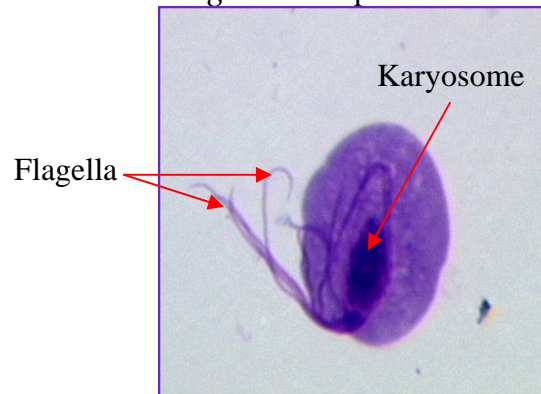
Cigar shaped Chromatin Body

Troph stage will have Pseudopods, an extruding cytoplasmic extension

Class *Mastigophora* Mode of Locomotion: Flagella

Scientific Name/ Common Name	Disease	Size/Shape	Laboratory Diagnostic	Source of Infection/ Intermediate Host/Vector	Sign/Symptoms	Treatments	Stats
<i>Trichomonas vaginalis</i>	Female: Trichomoniasis Male: Prostate & epididymis infections	Tear shaped in troph stage	Trophs in vaginal & prostate secretions, sediment in urine	Sexually transmitted. Trophs in vaginal & prostate secretions	Male: Asymptomatic Female: Vaginal discharge, burning, itching, chafing, increased urination	Metronidazole (Flagyl) for both sex partners	10-25% women in US infected
<i>Giardia lamblia</i>	Giardiasis/ backpacker's parasite	Pear shaped flagellate. "Eyes on a face"	Cysts or trophs in stool	Cysts in food & water or feces. Drinking water in the wilderness without purification	Abdominal discomfort, severe diarrhea, malabsorption, milk intolerance, weight loss	Boiling water (5-10 min) Quinacrine hydrochloride	<ul style="list-style-type: none"> Carried by elk, beavers, & deer 1 million infected/year
<i>Trypanasoma</i> <ul style="list-style-type: none"> <i>T. brucei gambiense</i> (W. Africa) <i>T. brucei rhodesiense</i> (E. Africa) <i>T. cruzi</i> (US, Cent & South Amer) 	African or American sleeping sickness, Chagas' disease		Blood smear	Tsetse fly (T.b.g & T.b.r.) or reduviid (triatomid) bug (T.c.)	Fever, headaches, nausea, vomiting, coma, death		Produce 1000 antigenic coats No cyst stage

Trichomonas vaginalis trophozoites



No cyst stage

Look for:

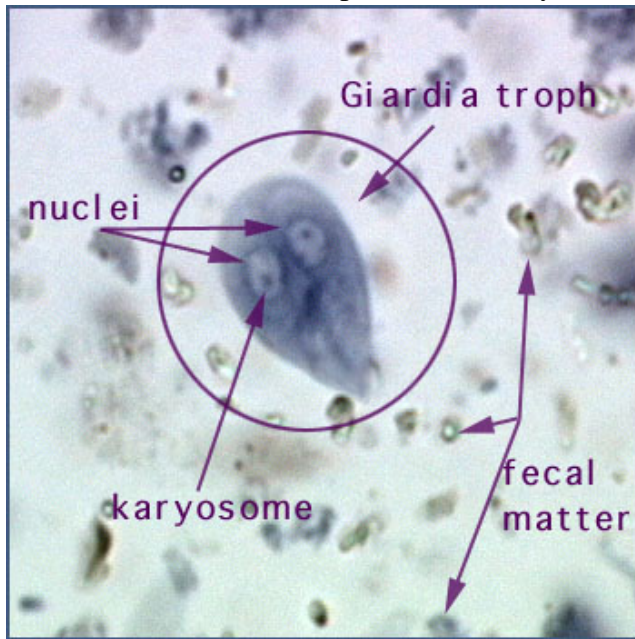
Tear shaped

3 to 5 flagella on anterior end

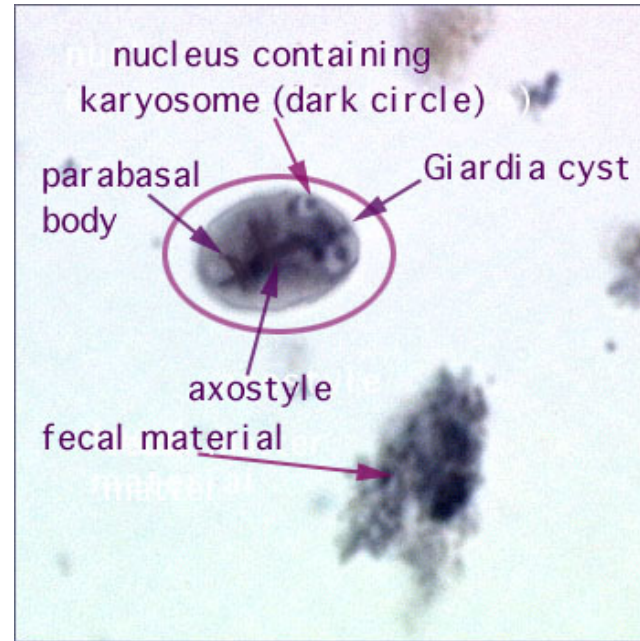
Nucleus with Karyosome

Purple stain

Giardia lamblia trophozoites and cysts



Troph



Cyst

Look for:

Troph: Pear shaped

Ovoid, concave sucking disc of ventral surface

Two nuclei, both with large central Karyosome

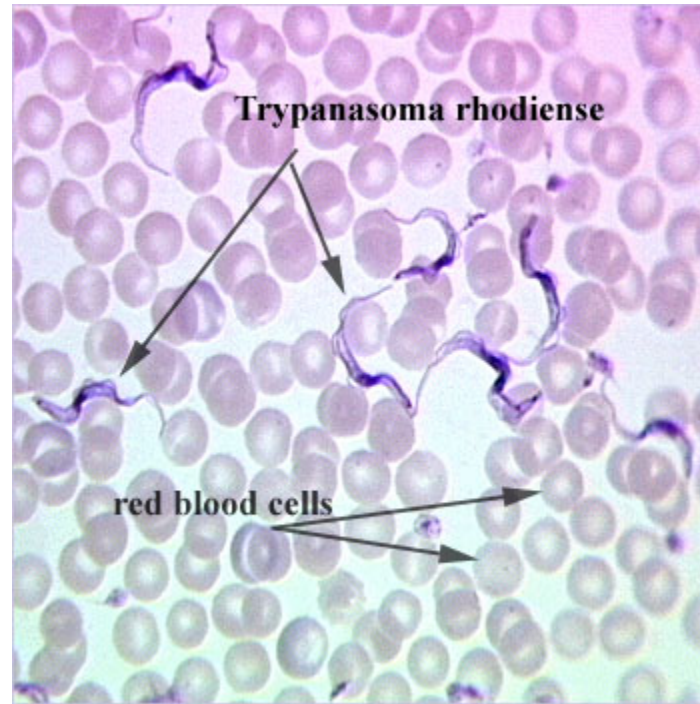
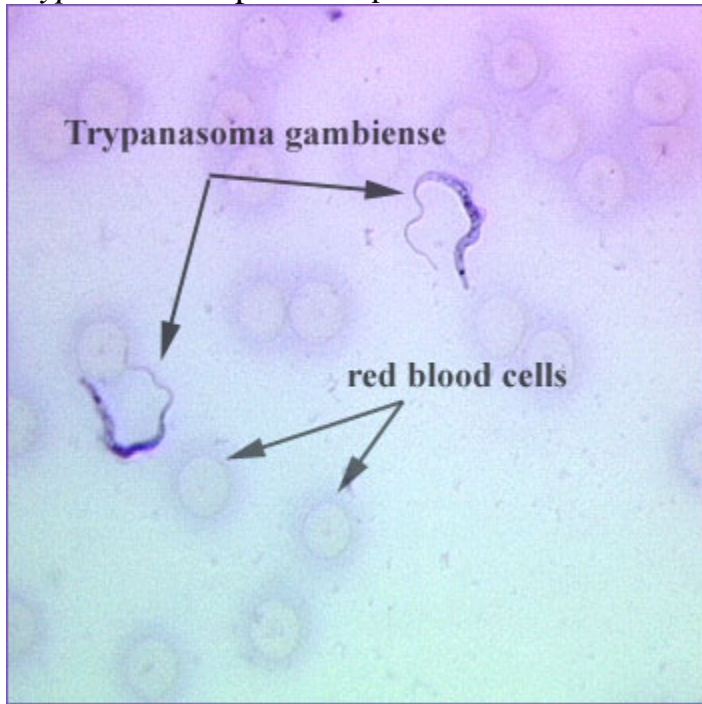
“Eyes on face” appearance

4 to 5 flagella maybe present

Cyst: Oval shape

2 to 4 nuclei

Trypanosoma species trophozoites



No cysts stage

Look for: Flagella

Found between blood cells in blood smears

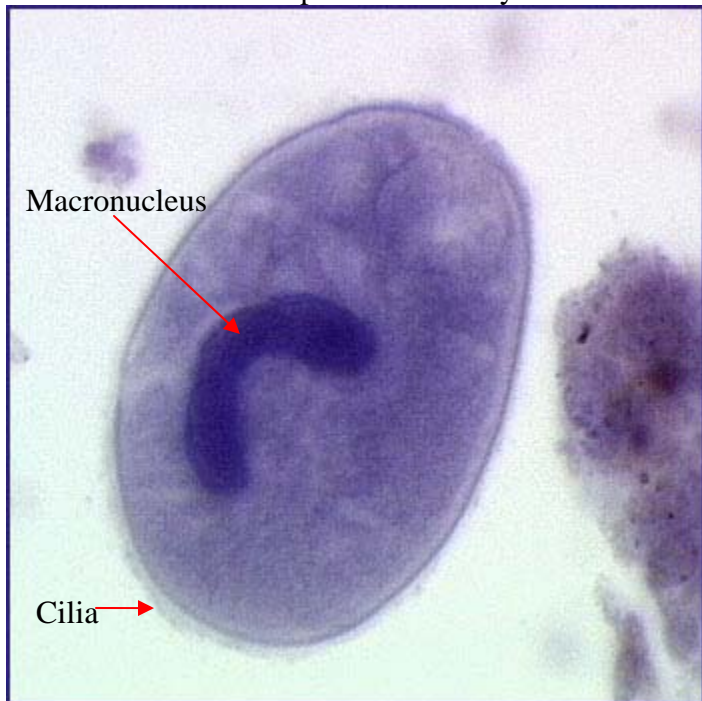
(Don't need to distinguish by species)

Class *Ciliata*

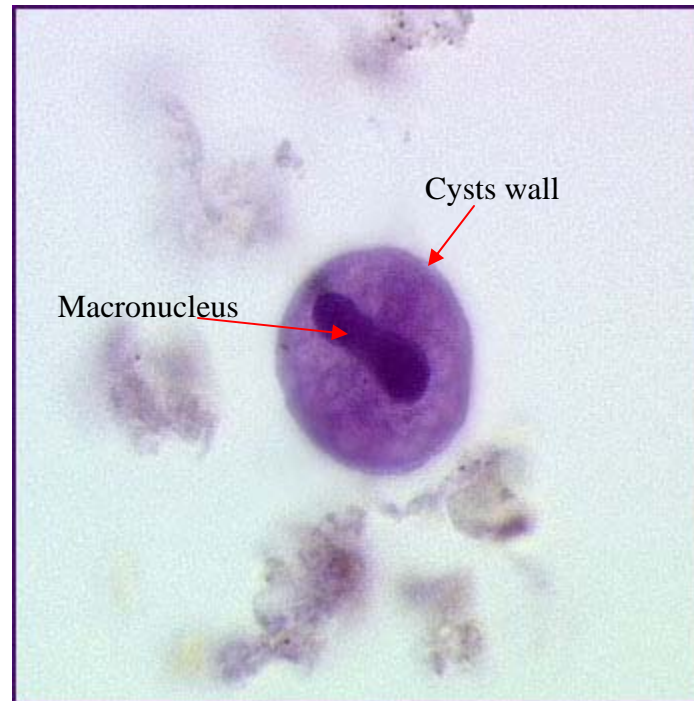
Mode of locomotion: Cilia

Scientific Name/ Common Name	Disease	Size/Shape	Laboratory Diagnostic	Source of Infection/ Intermediate Host/Vector	Sign/Symptoms	Treatments	Stats
<i>Balantidium coli</i>	Recurrent diarrhea alternating with constipation	Large, 200 micron	Cysts in stools	Ingested Feces of infected person	Diarrhea, constipation		<ul style="list-style-type: none"> Epidemic in US mental hospitals

Balantidium coli trophozoites and cysts



Troph



Cyst

Look for:

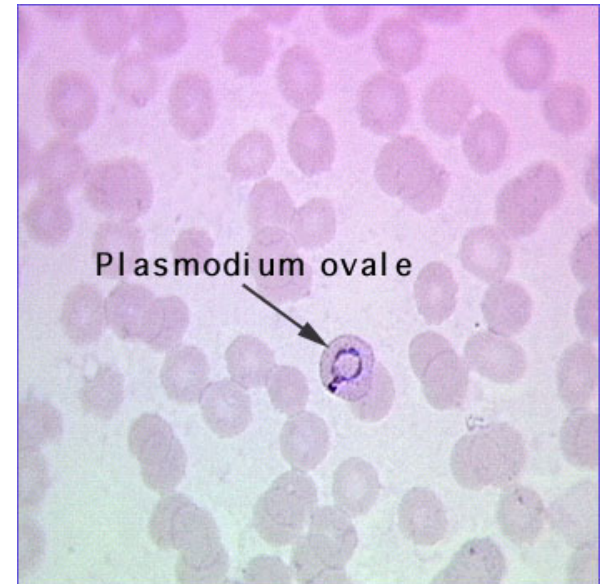
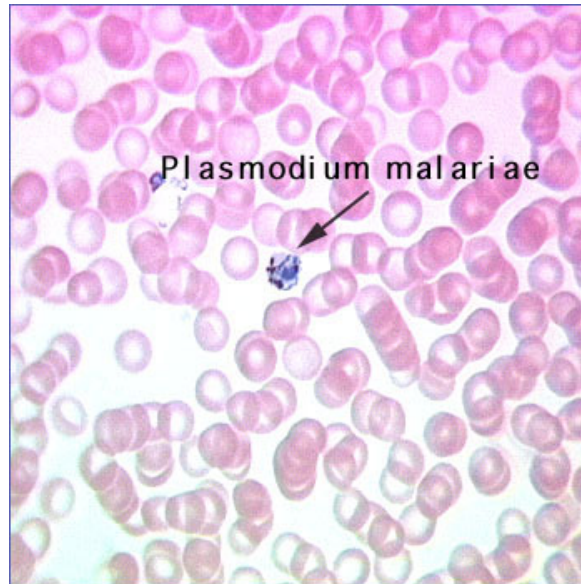
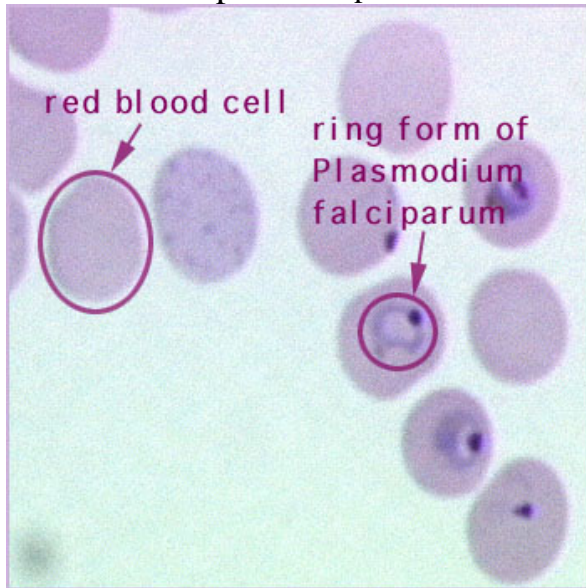
Troph: Large size
Cilia
Oval shape
Prominent long & kidney shaped macronucleus
(Micronucleus present but not usually visible)

Cysts: Spherical shape
No cilia
Cysts wall

Class *Sporozoa* / *Apicomplexa* Mode of locomotion: None, use spores for reproduction

Scientific Name/ Common Name	Disease	Size/Shape	Laboratory Diagnostic	Source of Infection/ Intermediate Host/Vector	Sign/Symptoms	Treatments	Stats
<i>Plasmodium</i> • <i>P. falciparum</i> • <i>P. vivax</i> • <i>P. malariae</i>	Malaria		Blood smear	<i>Anopheles</i> mosquito	Fever, chills, headache, muscle pain, sweating	<ul style="list-style-type: none"> • Mefloquine hydrochloride (Larium) • Kill mosquitos • Repellants & netting 	<ul style="list-style-type: none"> • 400 million (world) w/malaria
<i>Toxoplasma gondii</i>	Toxoplasmosis, Hydrocephaly- "Water on the brain" (congenital defect)	Crescent shaped, 6 microns long to 3 in width	Biopsied tissue or body fluids/serology, mouse inoculation	Cat feces (litter box), raw meat or transplacental (mother to infant)	Human Fetus: Congenital defects, retinochoroiditis, mental retardation (from water on the brain), convulsions, blindness, death	<ul style="list-style-type: none"> • Pyrimethamine (Daraprim) • Spiramycin (for pregnant women in Europe) 	
<i>Cryptosporidium parvum</i>	Traveler's diarrhea		Oocysts in stool with acid-fast stain, fluorescent stain or immunoassays	Water or feces, fecal-oral route	Profuse/watery diarrhea, abdominal cramping, n/v, fever, headache	<ul style="list-style-type: none"> • Microfiltration • Oral & parenteral rehydration therapy 	<ul style="list-style-type: none"> • Very resistant to disinfectants • Opportunistic infection of AIDS patients

Plasmodium species trophozoites



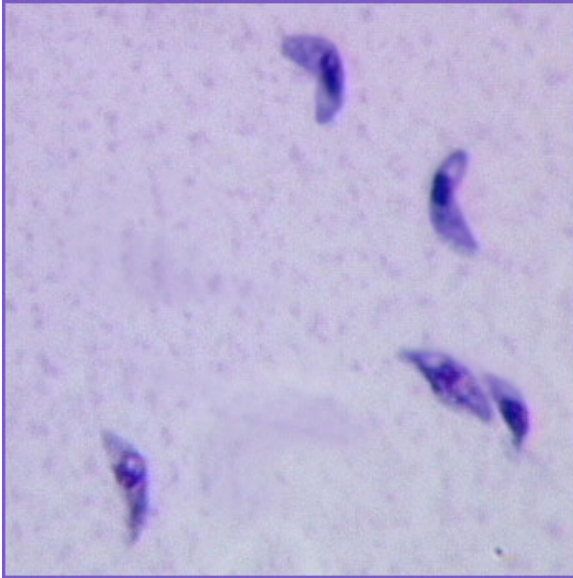
No cysts stage

Look for:

Ring found inside blood cells

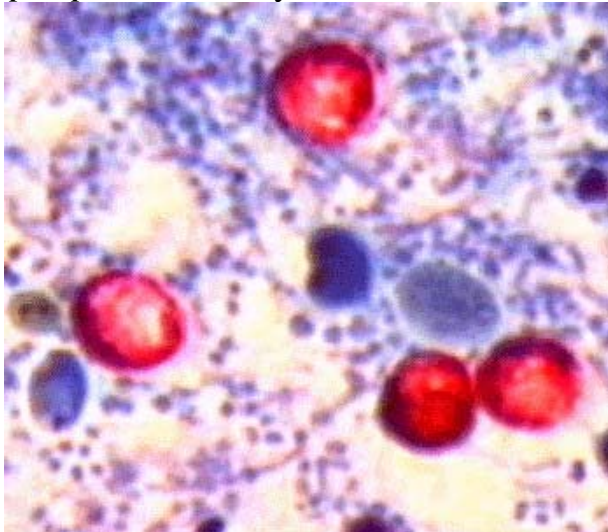
(Don't need to distinguish by species)

Toxoplasma gondii trophozoites



No cysts stage
Look for:
Bow or boomerang shaped
Nuclei

Cryptosporidium oocyst



Oocyst stage
Look for:
Bright red spheres in acid-fast stain

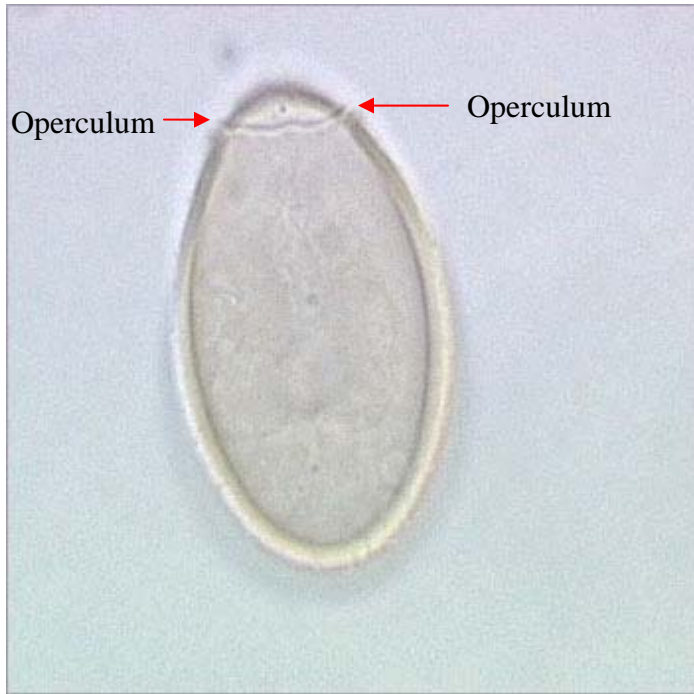
Platyhelminthes: Exercise 13

37. With the aid of your drawings on p. 13-13 and 13-14, identify:

Class *Trematoda*: Flukes

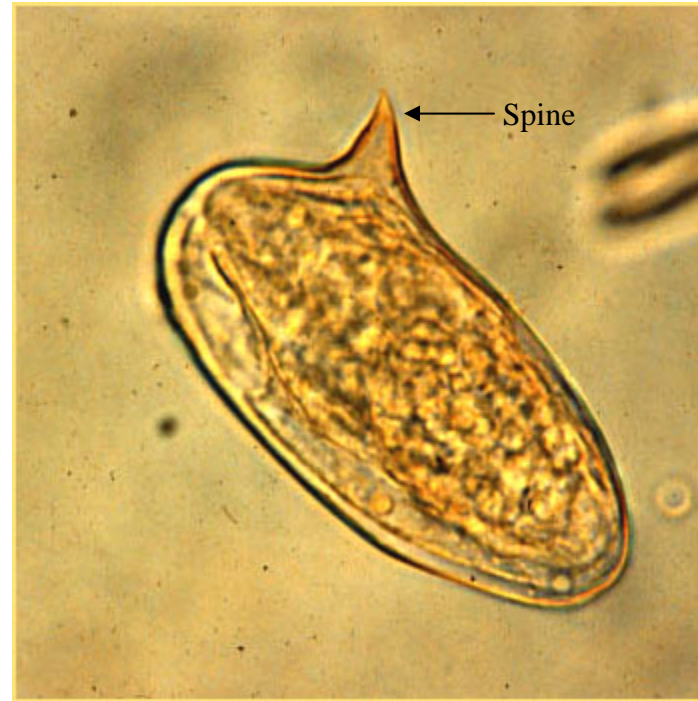
Scientific Name/ Common Name	Disease	Size/Shape	Diagnostic Stage	Infective Stage in Humans	Sign/Symptoms	Treatments	Stats
<i>Clonorchis sinensis</i> / Chinese liver fluke	Chinese liver fluke infestation	Adult: leaf shaped Ova: urn shaped 25-35 m	Ova in feces	Metacercaria in raw freshwater fish	Biliary obstruction, jaundice, diarrhea, liver pain, anemia, abdominal distress	Praziquantel	<ul style="list-style-type: none"> • Found in SE Asia • Monoecious = organism is male & female
<i>Schistosoma mansoni</i> / Blood fluke	Schistosomiasis/ bilharziasis	Leaf shaped	Ova in feces	Free-swimming cercaria in fresh water penetrate skin	Destruction of liver, lungs and/or urinary tract	Praziquantel & Oximiquine	<ul style="list-style-type: none"> • Dioecious = organism is male <u>or</u> female • 200 mil (world) • Burrows through skin

a. *Clonorchis sinensis* ova



Look for: Operculum (two shoulder or horn like projections)
at one end
Oval shaped

b. *Schistosoma mansoni* ova



Look for: Oval shaped
Spine projection

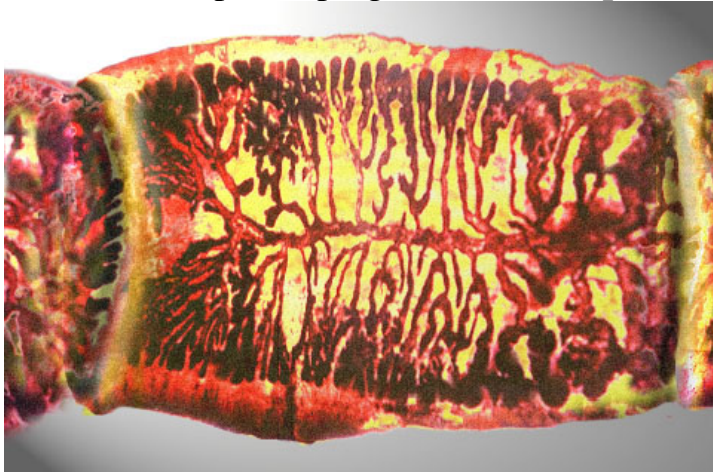
Route of transmission

**Free-swimming form (cercaria) which may penetrate
intact human skin and infection ensues**

Class *Cestoda*: Tapeworms

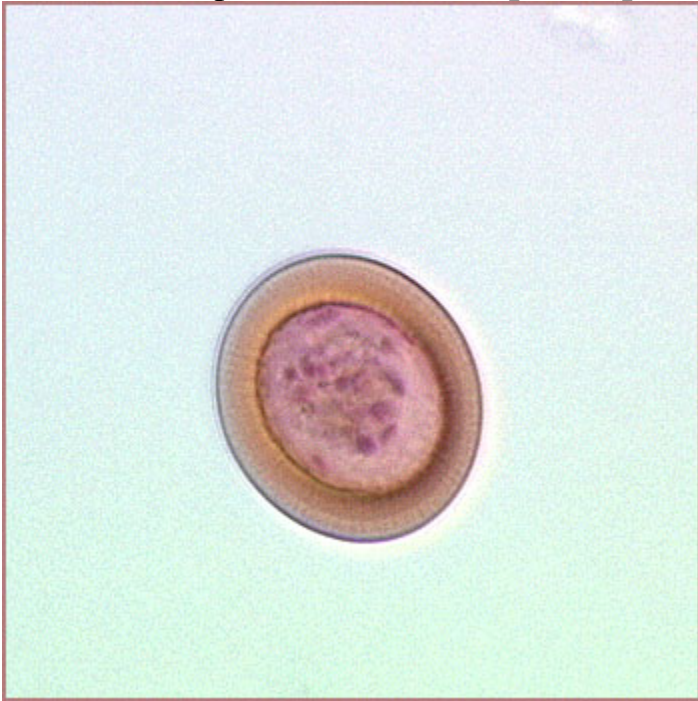Scientific Name/ Common Name	Disease	Size/Shape	Diagnostic Stage	Infective Stage in Humans	Sign/Symptoms	Treatments	Stats
<i>Taenia saginata</i> / Beef tapeworm	Taeniasis, beef tapeworm infestation	25 meters	Ova/proglottids in feces	Cysticercus	Brain cysts	Niclosamide	In US through rare steak
<i>Taenia solium</i> / Pork tapeworm	Taeniasis, pork tapeworm infestation, cysticercosis	Scolex has crown of hooks	Ova/proglottids in feces	Cysticercus or ova	Brain cysts, mimics brain tumor	Niclosamide	In Mexico, Central Amer, & American Hispanic communities
<i>Echinococcus granulosus</i> / None	Hydatid disease	A few millimeters long	Ultrasound imaging, magnetic resonance, serology	Ova	Depends on cyst location. Impairment of vital function. Death	Mebendazole, surgical removal of cyst	

c. *Taenia* species proglottid (beef or pork tapeworm)

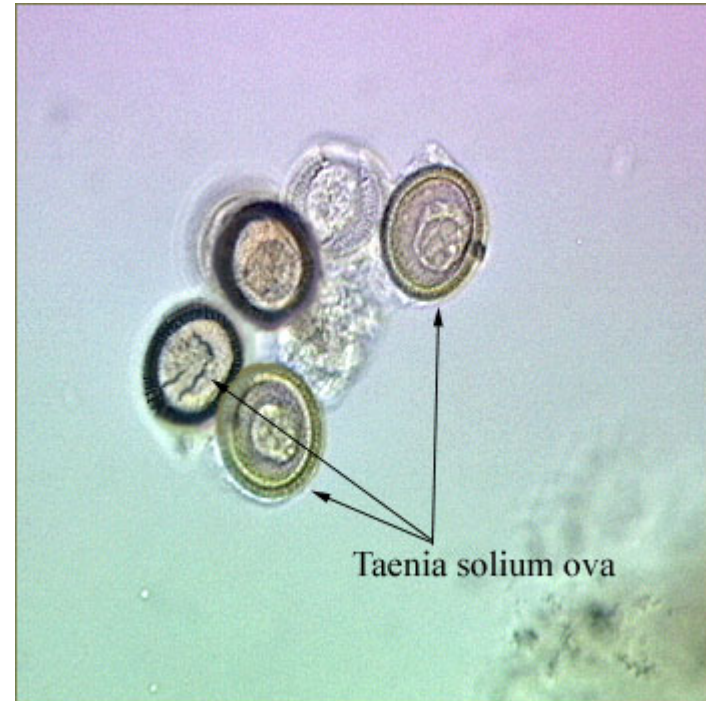

Look for: 10 to 20 branches (tree like) in its uterus
 Scolex at head (not shown)
 Body divided into proglottid (segments)
 (one proglottid shown here)

d. *Taenia* species ova (beef or pork tapeworm)



Taenia saginata (beef tapeworm)



Taenia solium (pork tapeworm)

Look for:

- Spherically shaped
- Covered in striated shell
- Six hook embryo inside
(*Taenia* and *Echinococcus* ova are identical)

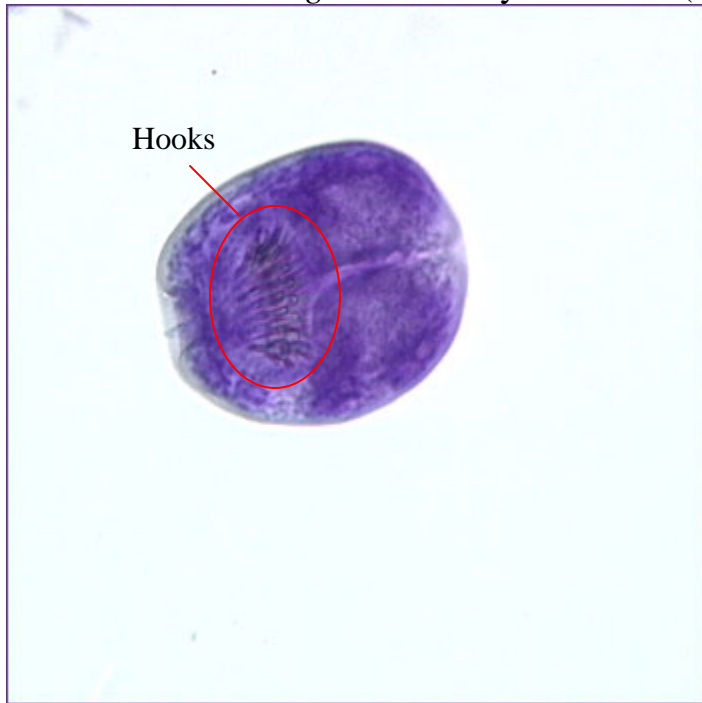
Route of transmission:

Raw or undercooked beef meat

Disease:

- Beef or pork tapeworm infestation
- Cysticercosis (from pork)

e. *Echinococcus granulosus* hydatid sand (also called hydatid cyst)



Look for:

Scolex with hooks visible

Appears oval shaped

(Taenia and Echinococcus ova are identical)

Route of transmission:

Carnivorous animals like dog's feces

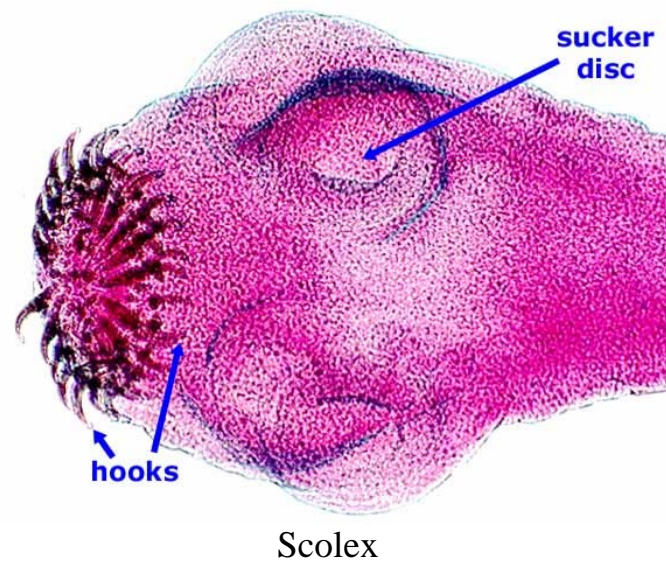
38. Define:

What is another name for egg?

Ova

What is the term for a tapeworm's head with 4 suckers and hooks by its mouth?

Scolex



What is the term for a tapeworm's segmented body?

Proglottid

What is a fluid filled sac with buds that form and grow into brood capsules where many immature scolices develop?

Hydatid sand (or hydatid cyst)

What is the term for an organism that is either male or female (separate animals)?

Dioecious

What is the term for an organism that is both male and female (both sexes occur in the same animal)?

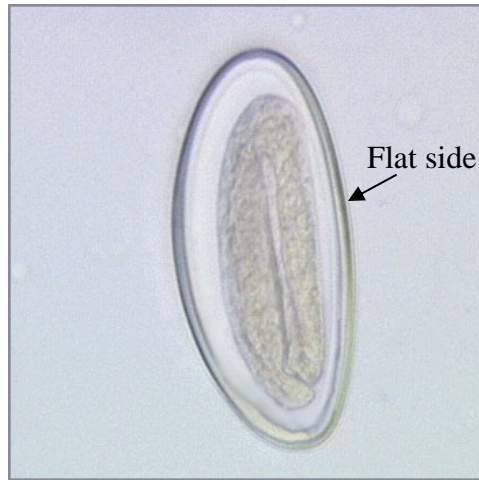
Monoecious

Nematoda (Aschelminthes): Exercise 14

39. With the aid of your drawings on p. 14-9, identify:

Scientific Name/ Common Name	Size/Shape	Diagnostic Stage	Source of Infection	Sign/Symptoms	Treatments	Stats
Ascaris lumbricoides / (none)	Female: Pencil thick/20-35 cm long Male: Smaller/ hook shaped tail	Ova in feces	Ingesting ova in soil, contaminated food or water	Hepatitis, abdominal pain, intestinal blockage, vomiting, diarrhea, fever Lungs: Severe pneumonitis, coughing spasms, allergic symptoms, asthmatic breathing	Antiminth (pyrantel pamoate) & Antepar (piperazine citrate)	1 billion infected (world) 1 million in US Female produces 26 million eggs/200,000 per day
Nector americanus / Hookworm	1.5 cm, blunt ends/ single thin hyaline shell	Ova in feces	Larvae in soil burrows through bare feet	Anemia, lethargy, mental & physical retardation	Vermox (mebendazole) or Antiminth (pyrantel pamoate)	500 million infected Consumes 0.15 mil per day/ 500 worms = 1 pt per day
Enterobius vermicularis / Pinworm	Male: 2-5 mm Female: 13 mm Long thin pointy body	Ova from perianal region by Graham's scotch tape method	Ingested ova in soil, contaminated food or water	Local itching, restlessness Hand to Mouth transmission, chronic itch at anus (pruritus ani)	Vermox Antiminth Povan (pyrvinium pamoate) causes red stool	209 million (world) 18 million (US & Can) No maturation stage outside host
Trichuris trichiura / whipworm	Long & thin, thick posterior	Ova in feces	Ingested ova in soil, contaminated food or water	Asymptomatic Chronic: Bloody diarrhea, abd. pain, headache, N/V, anemia, prolapse rectum	Vermox	3000-7000 eggs produced daily
Trichinella spiralis / (none)	Spiral formation in striated muscle	Muscle biopsy or serologic tests	Ingested larvae in raw or undercooked pork or bear meat	Depends on # of worms, size/age of host	Corticosteroids	1 pork chop = 10,000 larvae

a. *Enterobius vermicularis*



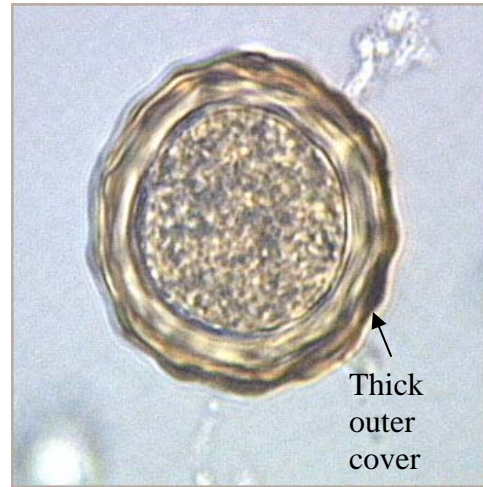
Common Name: Pinworm

Look for: Oval shape
One side flattened
Well-developed embryo possible

Route of transmission:
Ingested from hands or other fomites
(rag or mop head)

Diseases: Pinworm infection

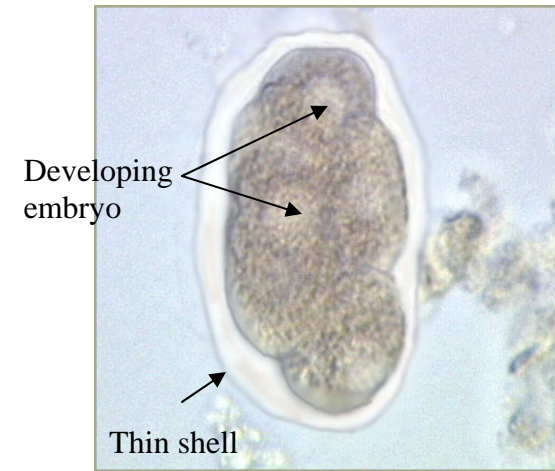
b. *Ascaris lumbricoides* (fertilized)



Look for: Thick, transparent, hyaline shell
covered with a thick outer layer

Route of transmission:
Ova may get into food or water from the soil

c. *Necatur americanus* ova



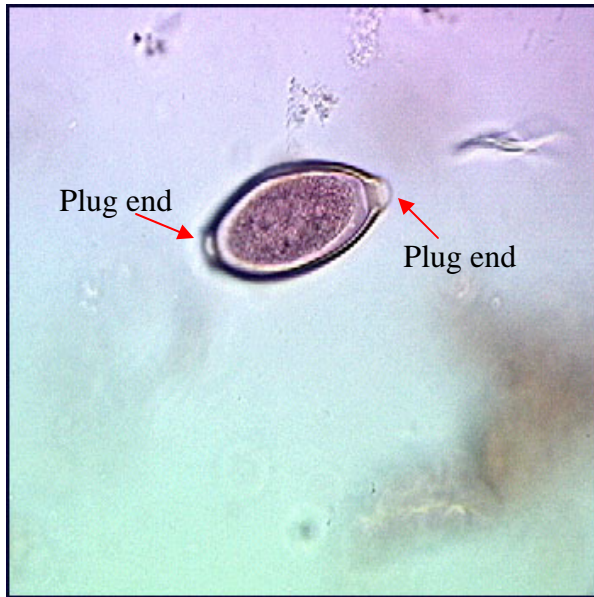
Common Name: Hookworm

Look for: Bluntly rounded ends
Single thin transparent hyaline
shell
Embryo development at cell
division stages

Route of transmission:
Contracted when mature larvae penetrate the
intact skin of a bare foot

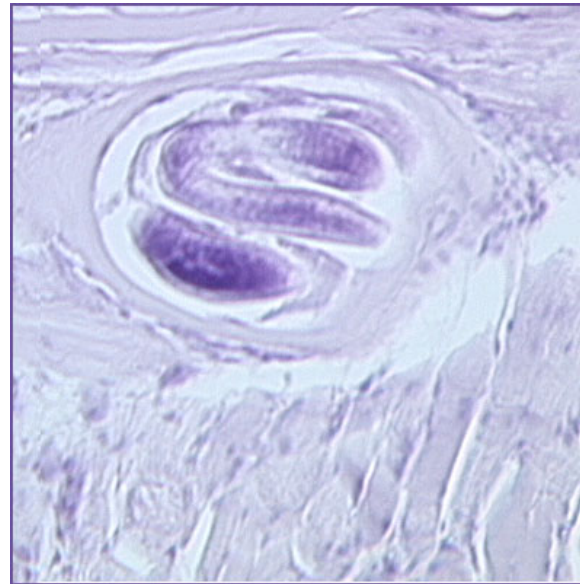
Diseases: Severe anemia

d. *Trichuris trichiura* ova

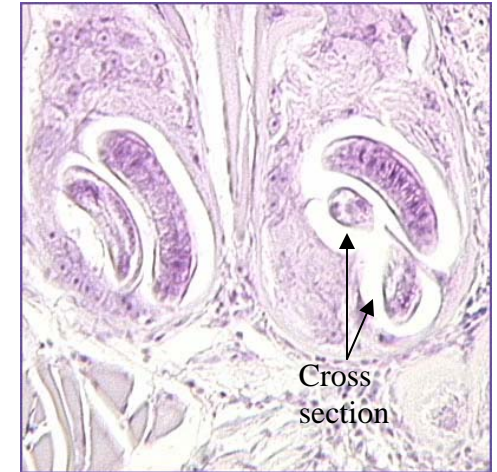


Look for: Translucent polar plug at each end

e. *Trichinella spiralis* larvae



Look for: Spiral form
Circular in cross section



Route of transmission:
Ingestion of larvae in raw or undercooked
pork, bear, or meat from any other
carnivorous animal

Diseases: Trichinosis